

PAPER • OPEN ACCESS

The role T1-weighted fluid attenuated inversion recovery (FLAIR) post contrast enhancement to improve image quality on MRI brain

To cite this article: R O Silfina *et al* 2021 *J. Phys.: Conf. Ser.* **1943** 012052

View the [article online](#) for updates and enhancements.

You may also like

- [Fully automatic detection of deep white matter T1 hypointense lesions in multiple sclerosis](#)
Lothar Spies, Anja Tewes, Per Suppa et al.
- [MR-guided dynamic PET reconstruction with the kernel method and spectral temporal basis functions](#)
Philip Novosad and Andrew J Reader
- [Investigation of a method for generating synthetic CT models from MRI scans of the head and neck for radiation therapy](#)
Shu-Hui Hsu, Yue Cao, Ke Huang et al.



244th Electrochemical Society Meeting

October 8 – 12, 2023 • Gothenburg, Sweden

50 symposia in electrochemistry & solid state science

▶ Deadline Extended!
Last chance to submit!

New deadline:
April 21
submit your abstract!

The role T1-weighted fluid attenuated inversion recovery (FLAIR) post contrast enhancement to improve image quality on MRI brain

R O Silfina¹, R Indrati², L R W Utami³

¹Radiology Diploma 3, Politeknik Kesehatan TNI AU Adisutjipto Yogyakarta, Indonesia

²Departement of Technique Radiodiagnostic and Radiotherapy, Poltekkes Kemenkes Semarang

³Radiology Diploma, Widya Husada University of Semarang, Indonesia

Corresponding author: redhaoktasilfina@gmail.com

Abstract. In general, head MRI examinations are performed using the T1-weighted and T2-weighted sequence techniques. T1-weighted is used to see the anatomy of the brain while T2-weighted aims to see the pathology or abnormalities that occur in the brain. Some of the clinics that are often found in head MRI include tumors, meningitis, epilepsy, intracranial lesions, metastases and others. The use of T1-weighted FLAIR sequences has a long duration of time, but produces a good image and by adding contrast media can show more sensitive abnormalities and minor abnormalities. The aim of the study was to analyze the application of the T1-weighted FLAIR Contrast Enhancement sequence to be more informative than the T1-weighted Contrast Enhancement sequence. This study uses the Systematic Literature Review (SLR) method. There are 80 literatures that have been selected in the initial stage. It was then followed by an extraction process, which produced 10 selected references. There are three stages of extraction, namely looking at the abstract title, identifying inclusion criteria, and identifying exclusion criteria. The results of this study indicate that the T1-weighted FLAIR Contrast Enhancement sequence is more sensitive to minor lesion abnormalities such as clinical parenchymal lesions, meningitis and leptomenigeal inflammatory disease than T1-weighted Contrast Enhancement.

1. Introduction

Magnetic Resonance Imaging (MRI) is a modality that functions to help doctors establish a diagnosis, by using a cross-sectional depiction technique based on the principle of magnetic resonance of the hydrogen atomic nucleus. MRI imaging techniques are relatively complex because the images produced depend on many parameters. This MRI has the ability to create coronal, sagittal, axial and oblique sections without much manipulation of the patient's body. If the parameter selection is right, the quality of the detailed picture of the human body will be clear, so that the anatomy and pathology of body tissues can be evaluated carefully [1].

In MRI, the term pulse sequence is known which can produce T1-Weighted Image (T1WI), T2-Weighted Image (T2WI), Spin Echo (SE), Proton Density (PD) and Fluid Attenuated Inversion Recovery (FLAIR) images with different intensities [2]. This resulting difference in intensity helps differentiate a pathology or abnormality. The difference in intensity on the results of MRI images with different pulse sequences has their respective advantages. Especially for displaying brain images,



namely Cerebro Spinal Fluid (CSF), White Matter and Gray Matter [2,3]. In general, MRI brain examinations are performed using the T1WI and T2WI sequence techniques. T1WI is used to view the anatomy of the brain while T2WI aims to see the pathology or abnormalities that occur in the brain area [3].

Some of the disorders that can be seen using the FLAIR sequence include tumors, meningitis, epilepsy, meningeal enhancement trauma, intracranial lesions, metastases and so on [3, 4]. FLAIR is a special inversion recovery pulse sequence with long time repetition (TR) and time echo (TE), and time inversion (TI) that effectively signals signals from cerebrospinal fluid (CSF). In the FLAIR T1 image the contrast enhancement on FLAIR imaging is the result of the mild T1 effect produced by the term TI; thus, the lesions showing improvement on T1-weighted Contrast Enhancement imaging also showed improvement T1-weighted FLAIR Contrast Enhancement images [5]. Image on FLAIR with enhanced contrast has many advantages for intracranial disease manifestations. T1-weighted FLAIR Contrast Enhancement imaging can be used as a primary or adjunct sequence for T1-weighted Contrast Enhancement in cryptic cases to increase diagnostic confidence and improve patient care [6,7]. A study has shown that image contrast is superior in T1 weighted FLAIR images, which also provide improved lesion to background and grey to white matter contrast to noise ratios. These indicate an important role for T1 weighted FLAIR sekuens in intracranial imaging and highlight its advantage over the more widely practiced T1 weighted FSE sekuens (T1WI SE) [5].

In patients with clinical metastatic melanoma, the contrast-enhanced T1-weighted sequence is the most sensitive sequence for detecting early metastases in the brain [7]. In theory, the FLAIR diagnostic image has a long TR time to produce a T2 weighted and is included in the T2-weighted image type, although the CSF on the diagnostic image appears dark. FLAIR sequences are not recommended to use contrast media because this sequence will also suppress the contrast media that is inserted [3]. Many studies have investigated flair in several cases, and there are still many pros and cons of using contrast media in FLAIR sequences. Research using the Systematic Literature Review method aims to evaluate and compare image information between T1-weighted Contrast Enhancement and T1-weighted Contrast Enhancement.

2. Method

This study uses a Systematic Literature Review method. The data source uses primary data in the form of published research journals. This method consists of three main stages: planning, acting and reporting. The planning stage is the identification of the need for a review to explain the reasons for the research, then compiling a review protocol. The next stage is action to conduct a review. This stage consists of several steps; namely the identification of the research section, the selection of articles that have been collected in the selection of the main study section, then data extraction from the selected articles in the data extraction section. The final stage is to summarize all findings from selected articles in the synthesis section.

a. Planning

This section is divided into two stages. First, determine the reasons and objectives of the study and compile a review protocol. The boundaries of this research are related journals in the last ten years (2010-2020). In this review literature research has research questions. The research questions are arranged in table 1, the criteria are grouped using the PICOC criteria.

Table 1. The research question criteria

Criteria	Description
Population	MRI Brain
Intervention	Image information of the sequences T1-weighted and T1-weighted FLAIR contrast enhanced
Comparation	T1WI FLAIR VS T1WI-weighted

Outcomes	Good image information between post contrast enhanced T1-weighted contrast enhanced I sequences and post contrast enhanced T1 weighted FLAIR contrast enhanced
Context	Look for good image information on various clinical MRI Brain

The research question in this systematic review is (RQ1) "Is the application of the T1-weighted FLAIR Contrast Enhancement sequence more informative than the T1-weighted Contrast Enhancement sequence?"

b. Identification of research

Papers resulted from search execution are selected according to the exclusion and inclusion criteria shown in Table 2. This keyword preparation aims to produce good results in accordance with the research question.

Table 2. Inclusion and exclusion criteria

Criteria	Description
Inclusion criteria	The study article has keywords related to T1-weighted contrast enhanced image information and T1-weighted FLAIR contrast enhanced in clinical terms in MRI Brain, only the most complete and newest one will be included.
	Article studies answering the research question
Exclusion criteria	Studies not written in English Studies that conducting the literature review Studies not published in relevant topic.

c. Data extraction and analysis

Searching the database using keywords, there were 80 articles identified. In the first stage the selection is done by reading the titles and abstract and 54 articles are obtained. In the second stage, 18 articles were selected using inclusion criteria. In the last stage there were 10 articles after applying the exclusion criteria. Finally, these 10 articles were used as the main study to answer research questions. The following is grouping the results into several stages as in Table 3.

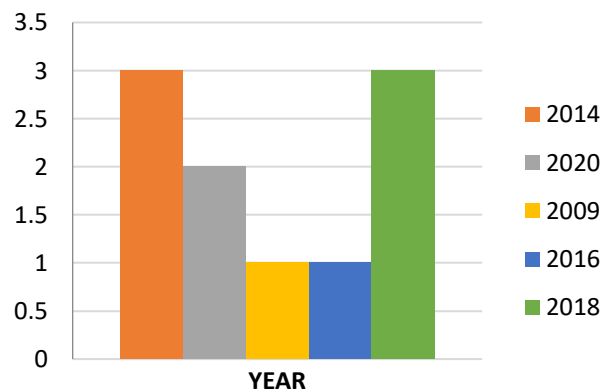
Table 3. Number of articles selected in selection process

Database	Discovery	1 st	2 nd	3 rd
Scopus	22	6	3	2
Science Direct	42	33	10	5
Google scholar	16	15	5	3
Total	80	54	18	10

The objective of this section is to take accurate research information in order to carry out the data synthesis from the primary studies. In this section, we analyze articles to get the main idea of the research. Then we group the articles by type as shown in table 4. The number of primary studies each year can be seen in figure 1.

Table 4. Articles Distribution by Type

Type	Study	Count	%
Journal	4, 6, 7, 8, 10, 13, 14	7	70%
Conference	1, 5, 12	3	30%

**Figure 1.** Articles distribution by year

3. Results and discussion

This study seeks the role of T1-weighted FLAIR contrast enhanced on MRI Brain in assessing image quality by answering the research question (RQ1), "Is the application of the T1-weighted FLAIR contrast enhanced sequence more informative than the T1-weighted Contrast Enhancement sequence?". FLAIR contrast enhanced T1WI sequence images have been shown to be superior to contrast T1-weighted images in the visualization of leptomeningeal inflammatory disease. Leptomeningeal disease can be more easily visualized on contrast-enhanced FLAIR images than on contrast-enhanced T1-weighted images because FLAIR imaging allows for a clearer distinction between increasing meninges and increasing cortical veins, cortical veins being less clearly enhanced on FLAIR images [10]. whereas in T1-weighted contrast enhanced, it is easier to detect progressively severe lesions surrounded by areas of hypointense edema. In addition, large Gd-accumulating lesions may not show an increase on the FLAIR contrast enhanced image because the signal-reducing T2 effect obscures the signal-enhancing T1 effect. Therefore, for intraparenchymic tumors, T1-weighted contrast enhanced may be better than FLAIR contrast enhanced imaging for detecting damaged lesions in the brain [6,7].

Since the increase in false positive findings is thought to be due largely to a marked vascular increase, the use of post contrast FLAIR imaging is expected to reduce the number of false positives in the evaluation of brain metastases. In theory, FLAIR can be used to suppress water (liquid) so that the signal intensity is low. In its application, the FLAIR sequence requires a very long TR to eliminate CSF signals. FLAIR is a phase of Inversion Recovery that utilizes CSF signals in a null point state. The eliminated CSF signal will be useful for detecting lesions in areas that are difficult to distinguish or hypertensive with CSF such as the sulcus or ventricles, this sequence in FLAIR uses a very long TR reaching 9000 ms and T1-weighted reaching 1800 ms to 2500 ms, FLAIR sequences are not recommended to use contrast media because this sequence will also suppress the contrast media being loaded [11].

By analyzing 10 selected articles it resulted in advantages and disadvantages between the T1WI post Contrast Enhancement and T1-weighted FLAIR Contrast Enhancement sequences, as described in Table 5.

Table 5. Advantages and disadvantages

Sequence	Advantages	Disadvantages	Studies
T1-weighted Contrast Enhancement	- High intensity - Shorter time - Shows abnormalities such as intra-axial tumors	- The accuracy of minor head clinics such as parenchymal lesions and meningitis is less accurate	3, 5, 8, 9
T1-weighted FLAIR Contrast Enhancement	- Accuracy against clinical parenchymal lesions, meningitis - Can visualize leptomeningeal inflammatory disease - Helps for evaluation of brain metastases	- Low intensity - Longer time	1, 4, 6, 7, 10, 15

In Table 5 we can see the advantages and disadvantages of each sequence, the two sequences complement each other and have their respective roles. Some hospitals use T1-weighted contrast enhanced more often, because this sequence already provides the information the doctor wants, and for the T1-weighted FLAIR Contrast Enhancement sequence it is very rarely used, this is because the scanning time for the T1-weighted FLAIR sequence is longer than the T1-weighted Contrast Enhancement [12].

4. Conclusion

This study has analyzed the advantages and disadvantages of T1-weighted FLAIR Contrast Enhancement and T1-weighted image information. Each sequence has been analyzed and identified for its use. the results show that the use of the T1-weighted FLAIR Contrast Enhancement sequence has a high informational value in the clinical detection of small lesions compared to T1-weighted Contrast Enhancement. The disadvantage of the post contrast enhanced FLAIR T1WI sequence is the long scanning time on the examination. There have been a lot of research on contrast flair, but the use of T1-weighted FLAIR Contrast Enhancement is still very few that have been researched and the reference references are still few. Future studies are expected to conduct direct research using the T1-weighted FLAIR Contrast Enhancement sequence with small clinical lesions on head MRI.

References

- [1] Rajul, Bhargava 2018 *West African Journal of radiology* **25**
- [2] Westbrook, Chaterine, Kaut, Carolyne and John Talbot 2011 *MRI in Practice*, Fourth Edition, Blackwell Science Ltd, United Kingdom
- [3] Ryan B K, Byrne N, Arvanitis L, Bhabad S and Byrne R 2016 *Surg Neurol Int.* **7** 21
- [4] Joeng, Boseul 2014 *Journal of the Korean Society of Magnetic Resonance in Medicine*
- [5] Alkan O, Kizilkilic O, Yildirim T, Alibek S 2009 *Diagn Interv Radiol.* **15** 2 75-80
- [6] Dickinson P J, Sarah J-W, Cissell D D 2018 *Vet Radiol Ultrasound* **59** 4 432-443
- [7] Lee E K, Lee E J, Kim S, Lee Y S 2016 *Korean J radiol*, **17** 1 127-141
- [8] Deike-Hofmann K, Thunemann D, Breckwoldt M O, Schwarz D, Radbruch A, Enk A, Bendszus M, Hassel J, Schlemmer H P, Baumer P 2018 *PLOS ONE* **13** 3 1-13

- [9] Tonarelli L 2013 *Magnetic Resonance Imaging of Brain Tumor*, Cewebsource.com Westbrook, Catherine, 2014, *Handbook of MRI Technique, Fourth Edition*, Blackwell Science Ltd., United Kingdom
- [10] Vaswani A K, Nizamani W M, Ali M, Aneel G, Shahani B K, Hussain S 2014 *ISRN Radiology* 578986 1-7
- [11] Kim H J 2014 *International Journal of Infectious Diseases* **24** 37-39
- [12] Kohrmann M, Struffet T, Frenzel T, Schwab S, Doerfler A 2012 *Stroke* **43** 1 259-261
- [13] Davis T S, Nathan J E, Tinoco Martinez A S, De Vis J B, Turtzo L C, Latour L L 2020 *Plos One* **15** 7 1-11
- [14] Kamr, W H 2020 *Journal of Radiology and Nuclear Medicine*. Springer
- [15] Ahmad A, Azad S, Azad R 2015 *J 140 Clin Diagn Res*; **9**:TC08-TC12
- [16] Lee K M, Kim H J, Kim E, Choi B S, Bae Y J, Bae H J 2016 *American Journal of Roentgenology* **206** 6 1272-1275